



**ANATOMICAL PLANAR OF URINARY EXCRETORY ORGANS**

Tulanova Difuza

Andijan State Medican Institute , Uzbekistan

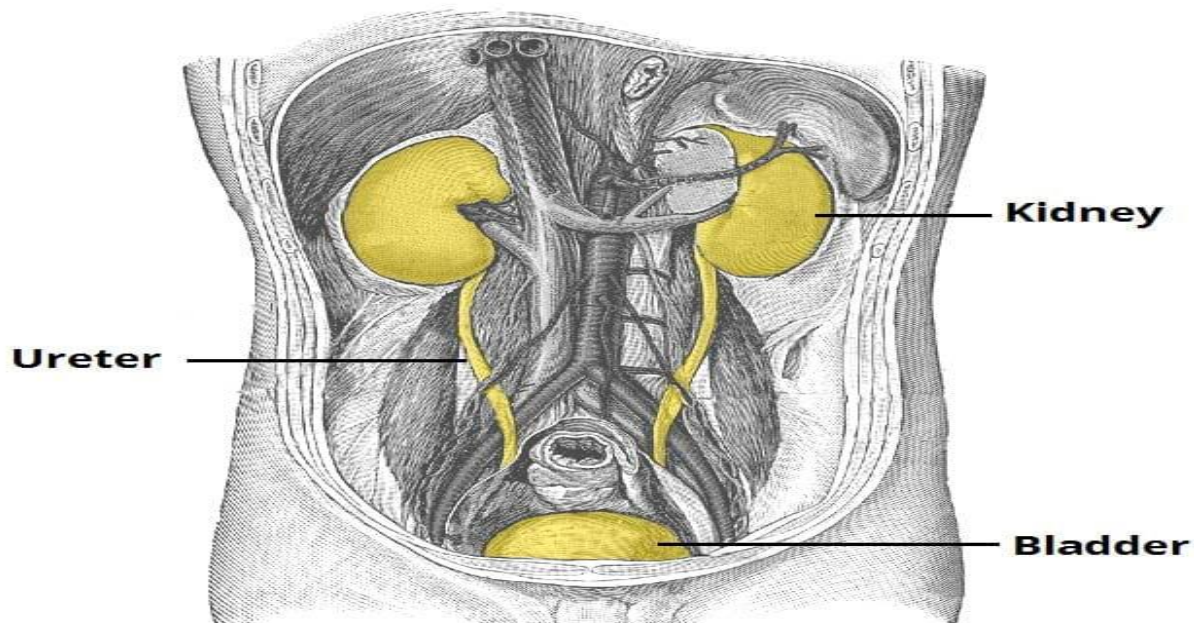
**Annotation:**

The kidneys are bilateral bean-shaped organs, reddish-brown in colour and located in the posterior abdomen. Their main function is to filter and excrete waste products from the blood. They are also responsible for water and electrolyte balance in the body.

**Keywords:** kidney , nephrons, ureter, bladder.

Metabolic waste and excess electrolytes are excreted by the kidneys to form **urine**. Urine is transported from the kidneys to the bladder by the ureters. It leaves the body via the urethra, which opens out into the perineum in the female and passes through the penis in the male.

In this article we shall look at the **anatomy of the kidneys** – their anatomical position, internal structure and vasculature.



© TeachMeAnatomy.com

Internally, the kidneys have an intricate and unique structure. The renal parenchyma can be divided into two main areas – the outer **cortex** and inner **medulla**. The cortex extends into the medulla, dividing it into triangular shapes – these are known as **renal pyramids**.

The apex of a renal pyramid is called a **renal papilla**. Each renal papilla is associated with a structure known as the **minor calyx**, which collects urine from the pyramids. Several minor calices merge to form a **major calyx**. Urine passes through the major calices into the **renal pelvis**, a flattened and

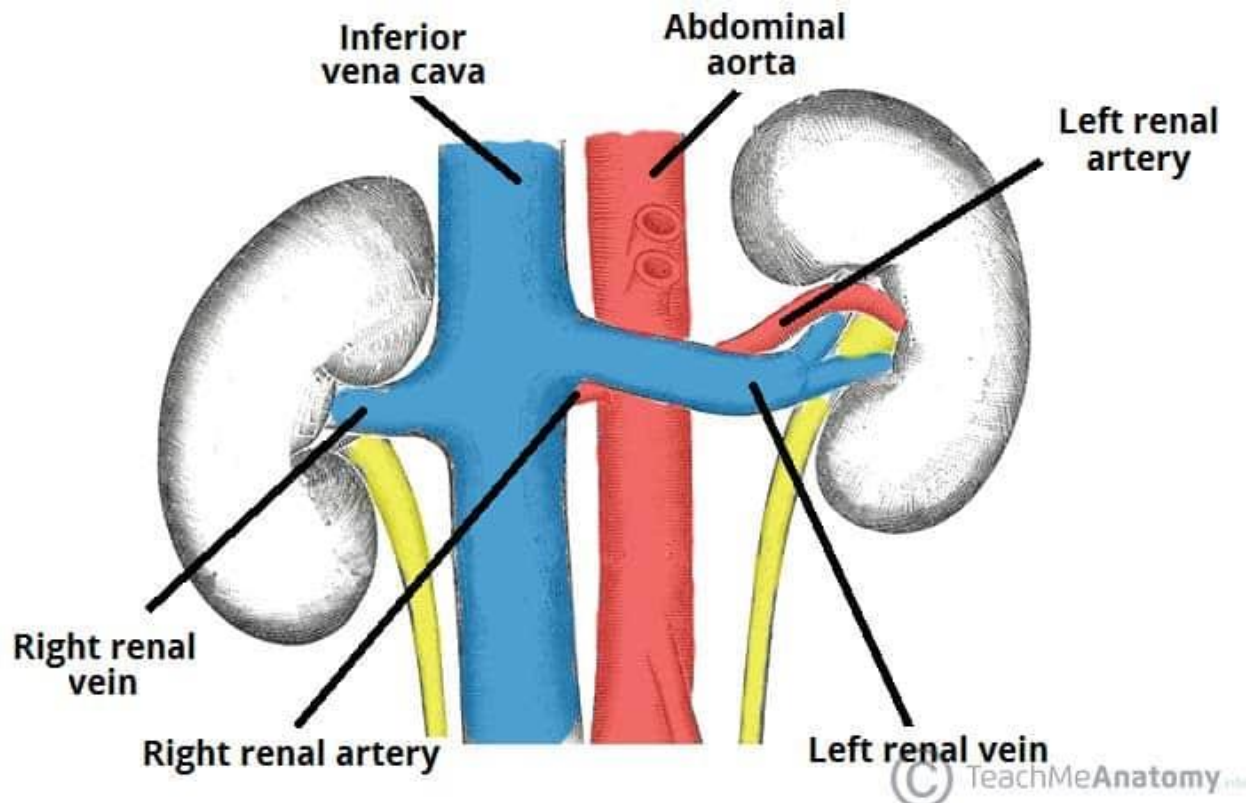


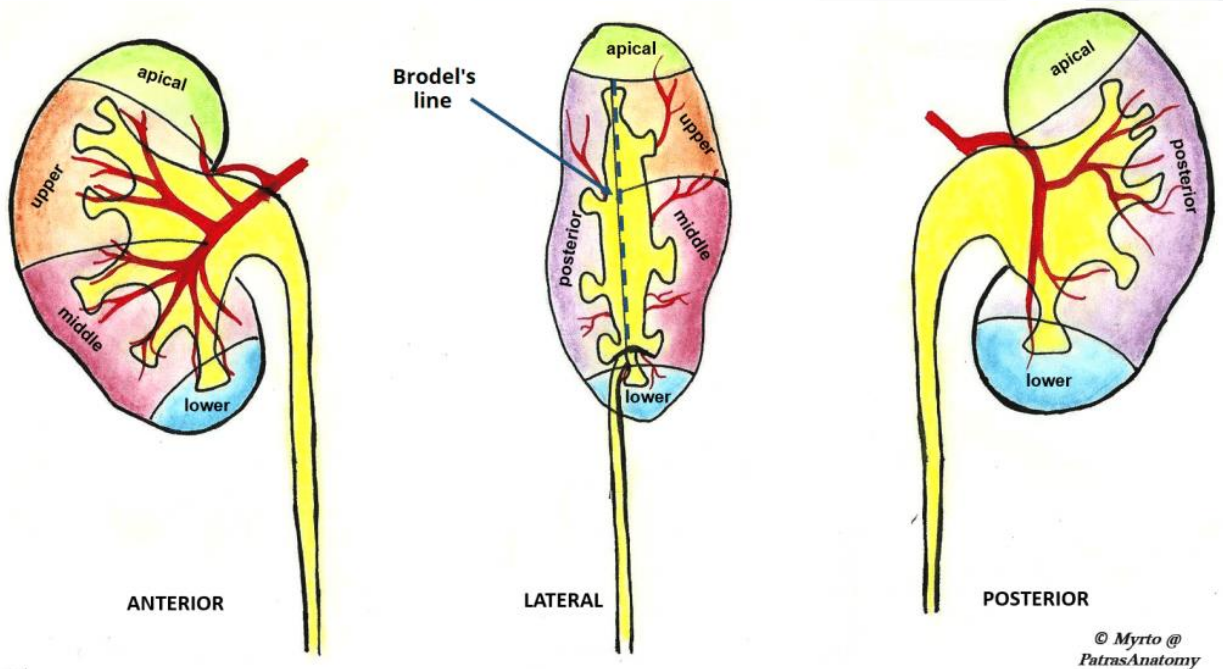
funnel-shaped structure. From the renal pelvis, urine drains into the ureter, which transports it to the bladder for storage.

The medial margin of each kidney is marked by a deep fissure, known as the **renal hilum**. This acts as a gateway to the kidney – normally the renal vessels and ureter enter/exit the kidney via this structure. The kidneys are supplied with blood via the **renal arteries**, which arise directly from the abdominal aorta, immediately distal to the origin of the superior mesenteric artery. Due to the anatomical position of the abdominal aorta (slightly to the left of the midline), the right renal artery is longer, and crosses the vena cava posteriorly.

The renal artery enters the kidney via the renal hilum. At the hilum level, the renal artery forms an **anterior** and a **posterior** division, which carry 75% and 25% of the blood supply to the kidney, respectively. Five **segmental arteries** originate from these two divisions.

The **avascular plane of the kidney** (line of Brodel) is an imaginary line along the lateral and slightly posterior border of the kidney, which delineates the segments of the kidney supplied by the anterior and posterior divisions. It is an important access route for both open and endoscopic surgical access of the kidney, as it minimises the risk of damage to major arterial branches.





The kidneys are drained of venous blood by the left and right **renal veins**. They leave the renal hilum anteriorly to the renal arteries, and empty directly into the inferior vena cava.

As the vena cava lies slightly to the right, the left renal vein is longer, and travels anteriorly to the abdominal aorta below the origin of the superior mesenteric artery. The right renal artery lies posterior to the inferior vena cava.

The kidneys excrete a variety of waste products produced by metabolism into the urine. The microscopic structural and functional unit of the kidney is the nephron. It processes the blood supplied to it via filtration, reabsorption, secretion and excretion; the consequence of those processes is the production of urine. These include the nitrogenous wastes urea, from protein catabolism, and uric acid, from nucleic acid metabolism. The ability of mammals and some birds to concentrate wastes into a volume of urine much smaller than the volume of blood from which the wastes were extracted is dependent on an elaborate countercurrent multiplication mechanism. This requires several independent nephron characteristics to operate: a tight hairpin configuration of the tubules, water and ion permeability in the descending limb of the loop, water impermeability in the ascending loop, and active ion transport out of most of the ascending limb. In addition, passive countercurrent exchange by the vessels carrying the blood supply to the nephron is essential for enabling this function.

The kidney participates in whole-body homeostasis, regulating acid–base balance, electrolyte concentrations, extracellular fluid volume, and blood pressure. The kidney accomplishes these homeostatic functions both independently and in concert with other organs, particularly those of the endocrine system. Various endocrine hormones coordinate these endocrine functions; these include renin, angiotensin II, aldosterone, antidiuretic hormone, and atrial natriuretic peptide, among others.



## Literature :

1. Lote CJ (2012). Principles of Renal Physiology, 5th edition. Springer. p. 21.
2. ^ Mescher AL (2016). Junqueira's Basic Histology, 14th edition. Lange. p. 393.
3. ^ Lv JC, Zhang LX (2019). "Prevalence and Disease Burden of Chronic Kidney Disease". *Advances in Experimental Medicine and Biology*. **1165**: 3–15. doi:10.1007/978-981-13-8871-2\_1. ISBN 978-981-13-8871-2. PMID 31399958. S2CID 199519437.
4. ^ Cotran RS, Kumar V, Fausto N, Robbins SL, Abbas AK (2005). *Robbins and Cotran pathologic basis of disease*. St. Louis, MO: Elsevier Saunders. ISBN 978-0-7216-0187-8.
5. ^ Kalantar-Zadeh K, McCullough PA, Agarwal SK, Beddhu S, Boaz M, Bruchfeld A, et al. (June 2021). "Nomenclature in nephrology: preserving 'renal' and 'nephro' in the glossary of kidney health and disease". *Journal of Nephrology*. **34** (3): 639–648. doi:10.1007/s40620-021-01011-3. PMC 8192439. PMID 33713333.